

Spinal Myoclonus in Subacute Combined Degeneration Caused by Nitrous Oxide Intoxication

Mei-Shian Wu^{1,2}, Yaw-Don Hsu¹, Jiann-Chyun Lin¹, Shih-Cheng Chen^{1,3}, and Jiunn-Tay Lee¹

Abstract- A 26-year-old patient developed ascending weakness and paresthesias. Megaloblastic anemia and mildly reduced serum vitamin B₁₂ (B₁₂) concentration were noted. Myoclonus-like muscular contractions appeared over four extremities and in the trunk. She admitted inhaling nitrous oxide (N₂O) as a euphoriant repeatedly at party. Following parenteral B₁₂ administration, her neurological deficit promptly resolved. This case demonstrated the abuse of N₂O is an important cause of subacute combined degeneration (SCD) of the spinal cord. To our knowledge, this is the first report of involuntary movements in a patient with N₂O intoxication. Although the mechanism remains unknown, involuntary movements similar to myoclonus should be considered as one of the extraordinary neurological manifestations of N₂O intoxication.

Key Words: Subacute combined degeneration (SCD), Nitrous oxide (N₂O), Magnetic resonance imaging (MRI), Myoclonus, Vitamin B₁₂

Acta Neurol Taiwan 2007;16:102-105

INTRODUCTION

Nitrous oxide (N₂O) abuse is relatively common^(1,2) and may cause significant neurological disability resulting from vitamin B₁₂ (B₁₂) deficiency. Subacute combined degeneration (SCD) of the spinal cord is a result of B₁₂ deficiency and characterized by weakness, abnormal sensations, mental problems and visual difficulties^(3,4). Common causes of B₁₂ deficiency are pernicious anemia, tropical sprue and gastric resection. SCD rarely

caused by N₂O intoxication. The mechanism of N₂O neurotoxicity is interference with B₁₂ bioavailability⁽⁵⁾ and the resulting neurological syndromes are indistinguishable from B₁₂ deficiency due to malabsorption or low dietary intake⁽⁶⁻⁸⁾. However a movement disorder is not a characteristic feature of N₂O neurotoxicity.

Diagnosing N₂O-induced neurologic disease may be difficult if the affected patient does not disclose her inhalation activity, or the examiner fails to inquire about it. In this issue we report a rare case of spinal myoclo-

From the ¹Department of Neurology, Tri-Service General Hospital, National Defense Medical Center, Taipei; ²Division of Neurology, Department of Internal Medicine, Chung Shan Hospital, Taipei; ³Division of Neurology, Department of Internal Medicine, Chi Mei Foundation Hospital, Liouying, Taiwan.

Received July 26, 2006. Revised September 8, 2006.

Accepted December 29, 2006.

Reprint requests and correspondence to: Jiunn-Tay Lee, MD, Department of Neurology, Tri-Service General Hospital, No. 325, Sec. 2, Cheng-Kung Road, Taipei, Taiwan.
E-mail: jjuuntay@ms26.hinet.net

nus presenting SCD patient caused by N₂O.

CASE REPORT

A 26-year-old woman suffered from weakness and numbness of both lower limbs for 2 days. She was previously healthy and denied history of abuse of toxic substances or illegal drugs. There was no history of gastrointestinal disease or deficient intake of B₁₂.

On neurological examination, her mental status, speech, and cranial nerves were normal. Strength was 3/5 in the lower limbs and 4/5 in the upper limbs. The tendon reflexes were absent and the plantar responses were bilaterally flexor. Sensory examination showed paresthesias in the hands and feet with markedly decreased vibratory sensation in her feet and legs following a distal-accentuating pattern.

On the 2nd hospital day, she further developed respiratory difficulty. She was initially diagnosed as Guillain-Barré syndrome (GBS). Plasma exchange was done but her symptoms did not improve. Results of the CSF studies were normal without evidence of albuminocytological dissociation (protein: 32 mg/dl, glucose: 58 mg/dl, chloride: 128 mmol/L). The anti-HCV, anti-HIV, Venereal Disease Research Laboratory test (VDRL) and thyroid function test were unremarkable. The NCV and

EMG studies disclosed sensory-motor demyelinating polyneuropathy. Blood biochemistry tests and blood cell counts revealed no abnormalities except higher MCV (101.8 fL). The B₁₂ level (normal value \geq 211 pg/ml) was low (187 pg/ml). She was prescribed intramuscular B₁₂ injections with a 1000 μ g daily for 7 days then 1000 μ g every week for 2 months under the impression of B₁₂ deficiency. The next day after B₁₂ injection, she developed multifocal, jerky movements over four extremities and in the trunk asynchronously. The brief and rapid twitching of muscle groups persisted during sleep with a lesser severity. The severity of myoclonic movements increased in the first four days, then they ceased spontaneously after the 7th day of B₁₂ therapy when the dose was reduced to 1000 μ g per week. EEG did not reveal any abnormality. Further electrophysiological examination could not be performed, because the patient refused investigation. When reviewing her history again, she disclosed a history of weekly N₂O inhalation for 2-3 months due to recreational purpose. The MRI of cervical spine revealed abnormal demyelinating lesion affecting the posterior column between C2 and C7 spine on T2-weighted images (Fig.). N₂O intoxication was finally diagnosed. Her symptoms completely resolved within 2 months after B₁₂ supplementation.

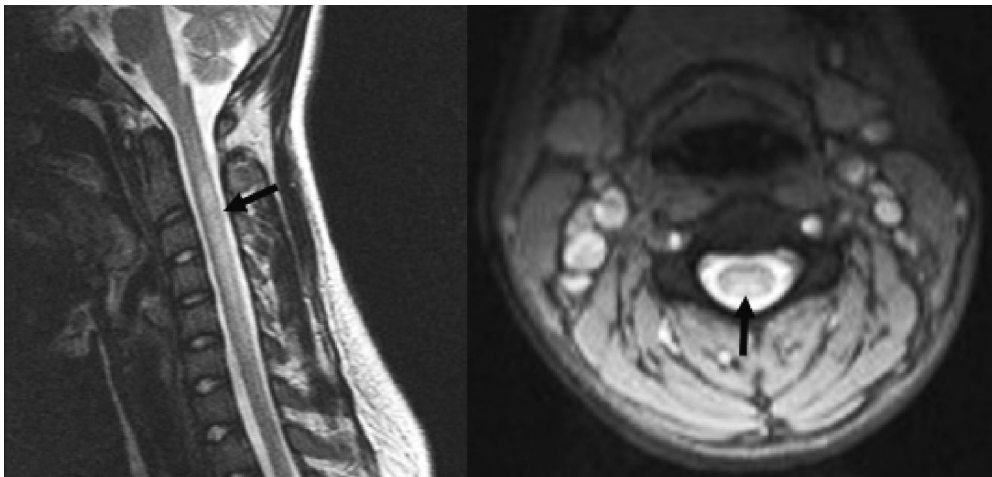


Figure. MR findings in a 26-year-old woman with a history of N₂O abuse presented with limb weakness, numbness and spinal myoclonus. (A) T2-weighted sagittal image shows increased signal intensity (black arrow) in the cervical spinal cord between C2 and C7. (B) T2-weighted axial image shows that the abnormal signal involves preferentially the posterior columns at the C4 level.

DISCUSSION

Under normal conditions, B₁₂ is converted in the cell cytoplasm to its active form, methylcobalamin, and bound as a cofactor to the enzyme methionine synthase, catalyzing the methylation of homocysteine to methionine. The products of this reaction are essential to the biosynthesis of myelin sheath protein, DNA, carbohydrate, and lipids⁽⁹⁾.

N₂O irreversibly inactivates methylcobalamin by oxidizing from its active constituent cobalt molecule (Co⁺) to the Co⁺⁺ and Co⁺⁺⁺ forms⁽¹⁰⁾. As methylcobalamin is depleted by N₂O, levels of methionine diminish and myelination cannot be maintained, leading to symptoms and signs of SCD. The etiologies of SCD include pernicious anemia (78.3%), tropical sprue (5.6%), gastric resection (4.2%), ileal resection (2.5%), jejunal diverticula (2.1%), dietary B₁₂ malabsorption (2.1%), multiple etiologies (2.8%), and etiology unknown (2.1%)⁽³⁾. N₂O neurotoxicity should be recognized as an important cause of SCD. In patients with N₂O neurotoxicity, the posterior columns are involved⁽⁵⁾ with loss of position and vibration senses, ataxia, broad-based gait, and, occasionally, Lhermitte sign. The corticospinal tracts may also be involved⁽⁵⁾, leading to weakness, spasticity, urinary and fecal incontinence, hyperreflexia, clonus, and extensor plantar response. Peripheral neuropathy as evidenced by axonal degeneration with or without demyelination in peripheral nerves is also seen⁽¹⁰⁾.

The patient was initially diagnosed of GBS due to ascending paralysis with respiratory difficulty, lower motor neuron signs (diminished DTR) and concealed history of N₂O abuse. The presence of N₂O abuse with myoclonus, abnormal nerve conductions and MRI of C spine, higher MCV, and low serum B₁₂ level confirmed the diagnosis. The patient in this report presented with paresthesias, profound loss of vibratory sensation ("large fiber" sensory loss) and preservation of pain and temperature ("small fiber" function). This clinical pattern also suggests that the dysfunction of the posterior column is due to N₂O neurotoxicity.

To our knowledge, there is no reported patient with

involuntary movements associated with N₂O intoxication. No sustained abnormal posture was observed in our patient, which might have suggested that the muscle contractions were part of a dystonic syndrome. They were multifocal, irregular, jerky movements and exaggerated with various stimuli, so were thought to be myoclonus.

Myoclonus can be classified into three groups, i.e. cortical, subcortical and spinal, based on the underlying physiological mechanism⁽¹¹⁾. The normal EEG did not favor cortical myoclonus in our patient. Subcortical myoclonus does not persist during sleep, except palatal myoclonus⁽¹²⁾. The persistence of myoclonus during sleep is a feature of spinal myoclonus⁽¹³⁾. Spinal myoclonus includes two types: first simple spinal segmental myoclonus, with focal repetitive rhythmic jerks and second propriospinal myoclonus with predominantly axial, arrhythmic flexor or extensor jerks involving many spinal segments⁽¹³⁾. In our opinion, the irregular, asymmetric extensor and flexor jerks persisting in sleep, developing on the basis of myelopathy in our patient resembled propriospinal myoclonus.

We propose the involuntary movements were related to B₁₂ therapy, because the involuntary movements happened on the next day after B₁₂ supplementation. There are a few reports of therapy-induced myoclonus in the patients with B₁₂ deficiency⁽¹⁴⁻¹⁶⁾. After a period of severe shortage of B₁₂ depleted by N₂O, the sudden availability of B₁₂ may have resulted in a temporary imbalance of the complicated metabolic pathways of cobalamin^(14,15).

Treatment for B₁₂ deficiency and N₂O toxicity is cobalamin and possibly methionine supplementation^(17,18). Parenteral vitamin therapy aimed at replenishing the total body pool is needed. Since most symptoms improve but do not resolve completely, early diagnosis and treatment are important.

In conclusion, N₂O interacts with vitamin B₁₂ resulting in selective inhibition of methionine synthase, a key enzyme in methionine metabolism. As methylcobalamin is depleted by N₂O, levels of methionine diminish and myelination cannot be maintained, leading to symptoms of SCD. N₂O intoxication should be recognized as one of the causes of SCD if no history of vegetarian or gastric

operation exists. N₂O intoxication should be considered in the differential diagnosis of acute ascending paralysis. Finally, spinal myoclonus can occur in patients with N₂O intoxication especially after the initiation of B₁₂ treatment. The pathogenic mechanism and the nature of the movement disorder are still not clear.

REFERENCES

1. Sahenk Z, Mendell JR, Couri D, et al. Polyneuropathy from inhalation of N₂O cartridges through a whipped-cream dispenser. *Neurology* 1978;28:485-7.
2. Brett A. Myeloneuropathy from whipped cream bulbs presenting as conversion disorder. *Aust N Z J Psychiatry* 1997; 31:131-2.
3. Healton EB, Savage DG, Brust JC, et al. Neurologic aspects of cobalamin deficiency. *Medicine (Baltimore)* 1991;70:229-45.
4. Metz J. Cobalamin deficiency and the pathogenesis of nervous system disease. *Annu Rev Nutr* 1992;12:59-79.
5. Green R, Kinsella LJ. Current concepts in the diagnosis of cobalamin deficiency. *Neurology* 1995;45:1435-40.
6. Blanco G, Peters HA. Myeloneuropathy and macrocytosis associated with nitrous oxide abuse. *Arch Neurol* 1983; 40:416-8.
7. Marie RM, Le Biez E, Busson P, et al. Nitrous oxide anesthesia-associated myelopathy. *Arch Neurol* 2000;57:380-2.
8. Kinsella LJ, Green R. 'Anesthesia paresthetica': nitrous oxide-induced cobalamin deficiency. *Neurology* 1995; 45:1608-10.
9. Ahn SC, Brown AW. Cobalamin deficiency and subacute combined degeneration after nitrous oxide anesthesia: a case report. *Arch Phys Med Rehabil* 2005;86:150-3.
10. Pema PJ, Horak HA, Wyatt RH. Myelopathy caused by nitrous oxide toxicity. *AJNR Am J Neuroradiol* 1998;19: 894-6.
11. Shibasaki H. Electrophysiological studies of myoclonus. *Muscle Nerve* 2000;23:321-35.
12. Blindauer K. Myoclonus and its disorders. *Neurol Clin* 2001;19:723-34.
13. Brown P, Thompson PD, Rothwell JC, et al. Axial myoclonus of propriospinal origin. *Brain* 1991;114:197-214.
14. Grattan-Smith PJ, Wilcken B, Procopis PG, et al. The neurological syndrome of infantile cobalamin deficiency: developmental regression and involuntary movements. *Mov Disord* 1997;12:39-46.
15. Ozer EA, Turker M, Bakiler AR, et al. Involuntary movements in infantile cobalamin deficiency appearing after treatment. *Pediatr Neurol* 2001;25:81-3.
16. Celik M, Barkut IK, Oncel C, et al. Involuntary movements associated with vitamin B12 deficiency. *Parkinsonism Relat Disord* 2003;10:55-7.
17. Yagiela JA. Health hazards and nitrous oxide: a time for reappraisal. *Anesth Prog* 1991;38:1-11.
18. Louis-Ferdinand RT. Myelotoxic, neurotoxic and reproductive adverse effects of nitrous oxide. *Adverse Drug React Toxicol Rev* 1994;13:193-206.